

# Journal of Cancer

## Main signs of ALL ophthalmic relapses

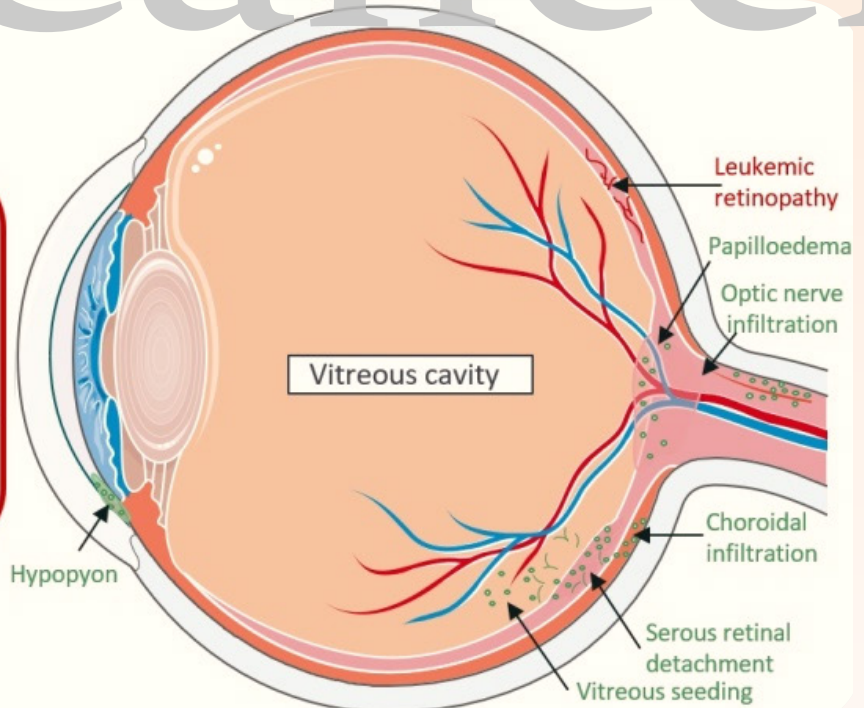
### Leukemic infiltration = blast cell infiltration

Hypopyon  
Vitreous seeding  
Serous retinal detachment  
Leopard spot retinopathy  
Choroidal infiltration  
Optic nerve infiltration  
+/- Papilloedema  
Etc

V  
E  
R  
S  
U  
S

### Leukemic retinopathy

Hemorrhages  
Roth Spots  
Cotton-wool spots  
Retinal venous dilation  
Retinal venous tortuosity  
Etc



**COVER FEATURE:** Novel Insights into Pediatric Acute Lymphoblastic Leukemia Ophthalmic Relapses from a Nationwide Cohort Study

*Solenne Le Louet, Véronique Icart, Marion Strullu, Arnaud Petit, Claire Freycon, Pascale Blouin, Jill Serre, Nicolas Rama, Yves Reguerre, et al.*



ISSN 1837-9664



9 771837 966005



**IVYSPRING**  
INTERNATIONAL PUBLISHER