

Colon

CAB068501

Female, age 84

Colon (T-67000)

Normal tissue, NOS (M-00100)

Patient id: 1958

Endothelial cells

Staining: **Low**

Intensity: **Weak**

Quantity: **>75%**

Cytoplasmic/

Location: **membranous
nuclear**

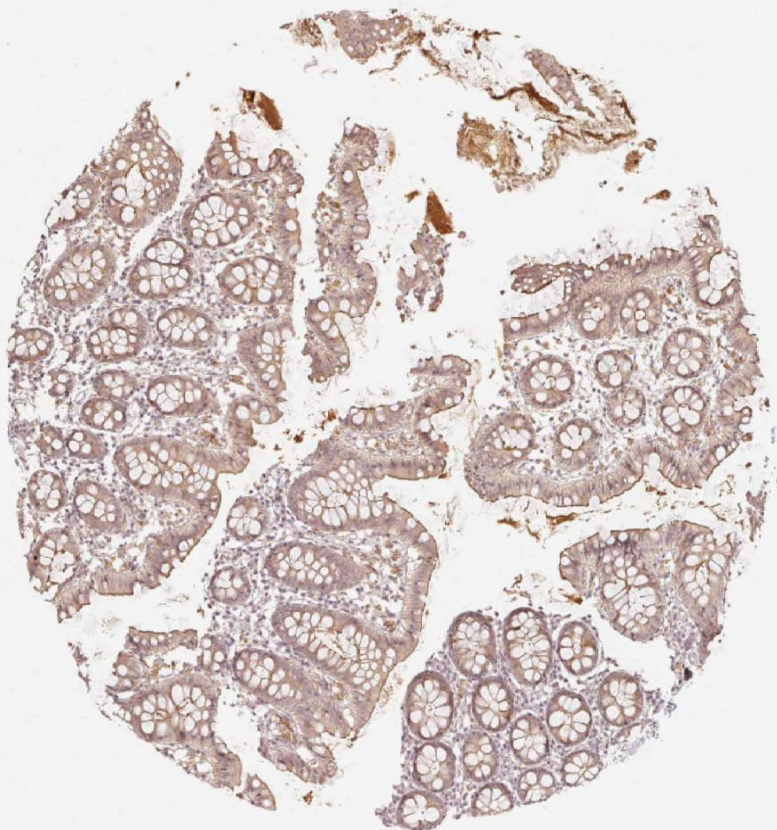
G lar cells


Staining: **Low**

Intensity: **Weak**

Quantity: **75%-25%**

Location: **Cytoplasmic/
membranous**





Colorectal cancer

CAB068501

Male, age 77

Colon (T-67000)

Adenocarcinoma, NOS

(M-81403)

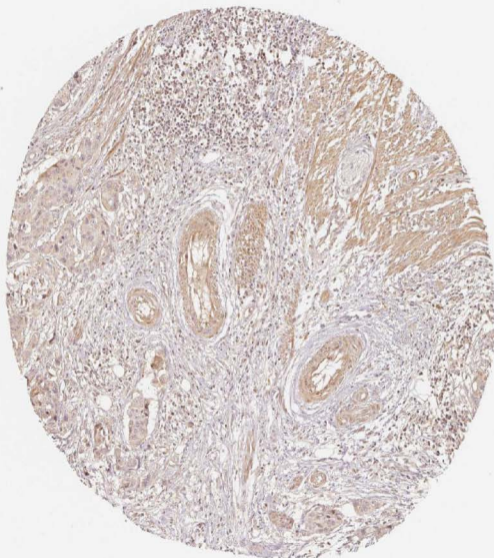
Patient id: 2931

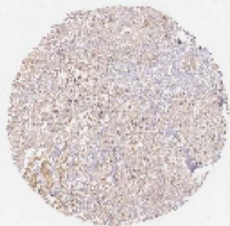
Tumor cells

Staining: **Not detected**

Intensity: **Negative**

Quantity: **None**





Colorectal cancer

CAB068501

Female, age 62

Rectum (T-68000)

Adenocarcinoma, NOS
(M-81403)

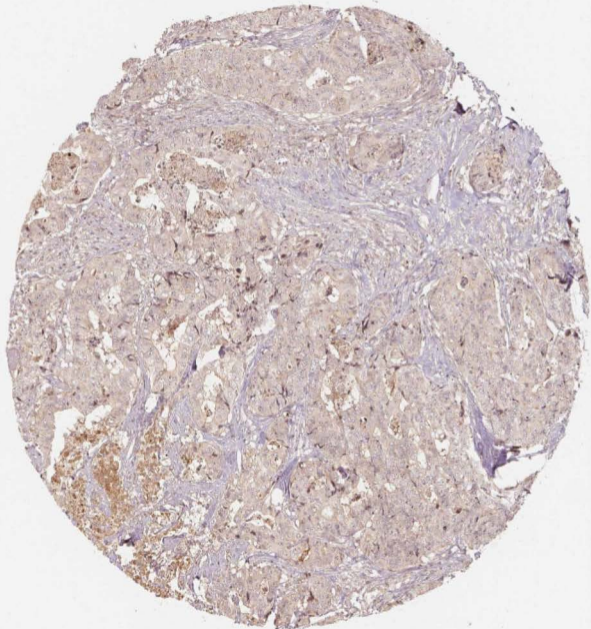
Patient id: 4752

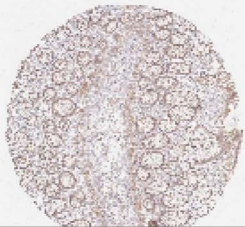
Tumor cells

Staining: **Not detected**

Intensity: **Negative**

Quantity: **None**





Rectum

CAB068501

Female, age 62

Rectum (T-68000)

Normal tissue, NOS (M-00100)

Patient id: 4381

Glandular cells

Staining: **Not detected**

Intensity: **Weak**

Quantity: **<25%**

Location: **Cytoplasmic/
membranous**

